

REVIEW ARTICLE

Ortho-perio Interrelationships: An Overview

¹Anjali Kapoor, ²Lalita Singhal, ³Saloni Kapoor, ⁴Anirudh Kapoor

ABSTRACT

Interaction between different specialties in dentistry are extremely important in establishing diagnosis and treatment planning. The interrelationship between orthodontics and periodontics often resembles symbiosis. In many cases, periodontal health is improved by orthodontic tooth movement, whereas orthodontic tooth movement is often facilitated by periodontal therapy. The orthodontic treatment is a double-action procedure, regarding the periodontal tissues. So it is of utmost importance to assess the need and outcome of interdisciplinary approach in different physiological, pathological or deliberate alterations in tooth positions to maintain harmonious periodontal and orthodontic relation.

Keywords: Cytokines, Mucogingival surgery, Osteoprotegerin, Periodontal ligament, Ridge augmentation.

How to cite this article: Kapoor A, Singhal L, Kapoor S, Kapoor A. Ortho-perio Interrelationships: An Overview. Int J Prev Clin Dent Res 2016;3(3):206-212.

INTRODUCTION

Cooperation, coordination, and interaction between different specialties in dentistry are extremely important in establishing diagnosis and treatment planning. The interrelationship between orthodontics and periodontics often resembles symbiosis. In many cases, periodontal health is improved by orthodontic tooth movement, whereas orthodontic tooth movement is often facilitated by periodontal therapy.

The orthodontic treatment is a double-action procedure, regarding the periodontal tissues, which may be sometimes very meaningful in increasing the periodontal health status and sometimes may be a harmful procedure that can be followed by several types of periodontal complications, namely, gingival recessions, bone dehiscences, gingival invaginations, and/or the formation of gingival pockets.

PERIODONTAL AND BONE RESPONSE TO NORMAL FUNCTION

Response to Normal Function¹

During masticatory function, the teeth and periodontal structures are subjected to intermittent heavy forces. Tooth

contacts last for 1 second or less; forces are quite heavy, ranging from 1 or 2 kg while soft substances are chewed up to as much as 50 kg against a more resistant object. When a tooth is subjected to heavy loads of this type, quick displacement of the tooth within the PDL space is prevented by the incompressible tissue fluid. Instead, the force is transmitted to the alveolar bone, which bends in response Tables 1 to 3.

Table 1: Physiologic Response to light Sustained Pressure Against the Tooth

Light pressure	Events
<1 seconds	PDL fluid incompressible, alveolar bone bends, piezoelectric signal generated
1-2 seconds	PDL fluid expressed, tooth moves within PDL space
3-5 seconds	Blood vessels within PDL partially compressed on pressure side, dilated on tension side; PDL fibers and cells mechanically distorted
Minutes	Blood flow altered, oxygen tension begins to change; prostaglandins and cytokines released
Hours	Metabolic changes occurring: Chemical; messengers affect cellular activity, enzyme levels change
4 hours	Increased camp levels detectable, cellular differentiation begins within PDL
2 days	Tooth movement begins as osteoclasts/osteoblasts remodel bony socket

Table 2: Physiologic response to heavy Sustained Pressure against a tooth

Heavy pressure	Events
3-5 seconds	Blood vessels within PDL occluded on pressure side
Minutes	Blood flow cut off to compressed PDL area
Hours	Cell death in compressed area
1-5 days	Cell differentiation in adjacent narrow spaces, undermining resorption begins
7-14 days	Undermining resorption removes lamina dura adjacent to compressed PDL, tooth movement occurs

Table 3: Periodontal tissue response to orthodontic therapy

Type of force	Tissue response
Light forces	PDL is ischemic with simultaneous bone formation and resorption, causes continuous tooth movement
Moderate forces	PDL strangulation causing delay in bone resorption
Heavy forces	PDL on the pressure side is crushed leading to local degeneration and ischemia = hyalinization = more delay in tooth movement

¹Professor and Head, ²Resident, ^{3,4}Student

^{1,2}Department of Periodontology, RUHS College of Dental Sciences, Jaipur, Rajasthan, India

^{3,4}All India Institute of Medical Sciences, New Delhi, India

Corresponding Authors: Lalita Singhal, A-10, Jawahar Park Khanpur, New Delhi, India, Phone: +919950232153, e-mail: lolita25@yahoo.in

Cascade of Events that Follow after Application of Orthodontic Force: The Role of Inflammation in Orthodontic Tissue Remodeling (Fig. 1)

As we apply orthodontic force on the tooth, various events at the microscopic level occur, based on the current understanding (Fig. 1):

The sequence of events after the application of mechanical forces with the help of orthodontic appliances can thus be outlined as:²

- Movement of PDL fluids from areas of compression into areas of tension.
- A gradual development of strain in cells and ECM in the parodontal tissues involved.
- Release of phospholipase A2 and cleavage of phospholipids leading to release of PGE2 and leukotrienes.
- ECM remodeling and signal transduction through integrin transmembrane channels.
- Cytoplasmic alterations and release of 2nd messengers of tooth movement—cAMP and cGMP, inositol phosphates, and calcium and tyrosine kinases.
- Release of kinases, such as protein kinase A, kinase C, and Mitogen-activated protein MAP kinases.
- Direct transduction of mechanical forces to the nucleus of strained cells through the cytoskeleton, leading to activation of specific genes.
- Release of neuropeptides (nociceptive and vasoactive) from parodontal afferent nerve endings.
- Interaction of vasoactive neuropeptides with endothelial cells in strained parodontal tissue.

- Adhesion of circulated leukocytes to activated endothelial cells.
- Migration by diapedesis of leukocytes into the extravascular space.
- Synthesis and release of signaling molecules by leukocytes that have migrated into the strained parodontal tissues.
- Interaction of various types of parodontal cells with the signal molecules released by the migratory leukocytes.
- Activation of the cells to participate in the modeling and remodeling of the parodontal tissues.

The above-stated cascade of events, in fact, may be a brief summary of the current understanding of a whole lot of complex activities and interactions occurring in the PDL and alveolar bone after the application of primary stimulus, such as mechanical force or action of hormones. Certain important modes of actions of chemical mediators and their complex, internal interactions.

Role of Prostaglandins in Mediating Orthodontic Tooth Movement

Classically, prostaglandins as one of the chief mediators of inflammation cause an increase in intracellular cAMP and calcium accumulation by monocytic cells, which then modulates and activates osteoclastic activity. (It is to be noted that elevation in cAMP is not only affected by PGE2s alone, but also influenced by substance P, VIP, calcitonin gene—related peptide and many others).

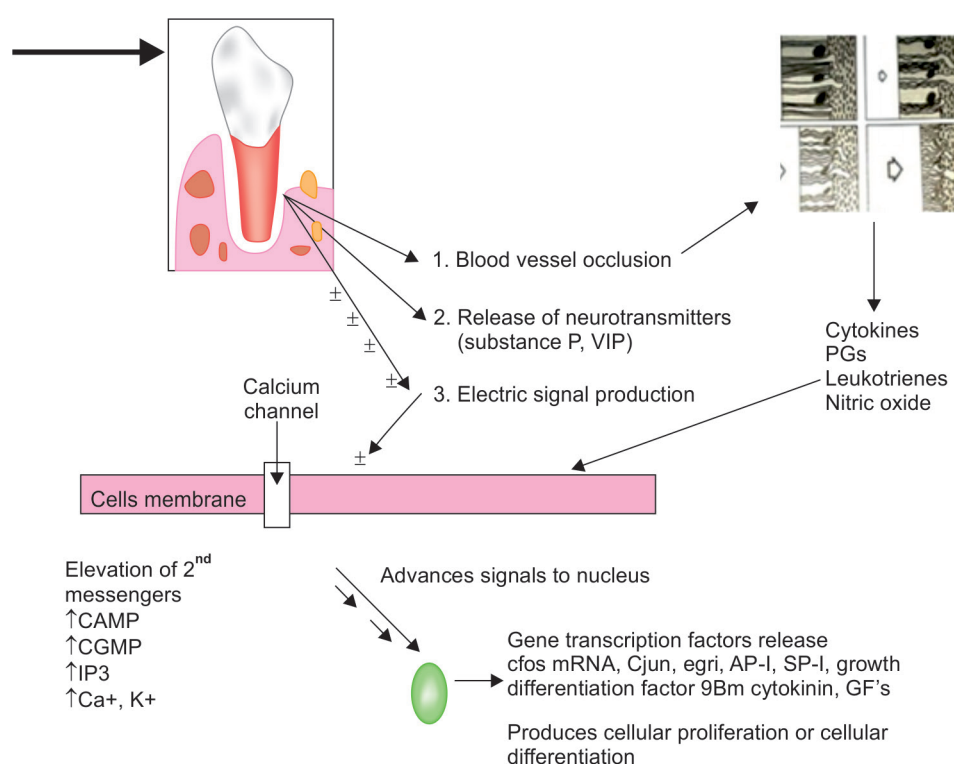


Fig. 1: Cascade of histological events during orthodontic tooth movement

Cytokines and Growth Factors in Orthodontic Tooth Movement

The early phase of orthodontic tooth movement involves an acute inflammatory response characterized by periodontal vasodilatation and migration of leukocytes out of PDL capillaries. The released inflammatory mediators, such as prostaglandins and IL-1 interact with bone cells. Cytokines secreted by leukocytes may interact directly with bone cells or indirectly, via neighboring cells, such as monocytes/macrophages, lymphocytes, and fibroblasts.^{3,4} Cytokines released have multiple activities, which include bone remodeling, bone resorption, and new bone deposition.

RANK-RANKL-OPG

The receptor activator of nuclear factor kappa B ligand (RANKL), its decoy receptor (RANK), and OPG were found to play important roles in regulation of bone metabolism.⁵ Evidences suggest osteoblast itself regulates the differentiation of osteoclast.^{6,7} The talk between an osteoblast and an osteoclast is accomplished through an osteoblast membrane bond RANKL, which can interact with osteoclast precursors to cause them to differentiate into osteoclasts. Another membrane bond molecule and its bonding ligand OPG can develop to block RANKL and prevent osteoclast formation.⁵ Extensive studies done by Theoleyre et al.,⁸ Kanzaki et al.,⁹ and Yamaguchi et al.¹⁰ have demonstrated that

RANKL promotes osteoclastogenesis while OPG inhibits this effect.

Detection of Mechanical Strain by Bone Cells

Researches indicate that the cells responsible for sensing mechanical strains by orthodontic tooth movement involving application of forces and movements from wires through brackets to teeth in the bone are osteoblasts, or osteocytes, or both.^{11,12} Three theories have been suggested on how these cells sense mechanical strain and how then the stimuli are passed into the cell and from one cell to another.

- Strain-released potentials
- Activation of ion channels
- Extracellular matrix and cytoskeleton reorganization.

INTERDISCIPLINARY TREATMENT

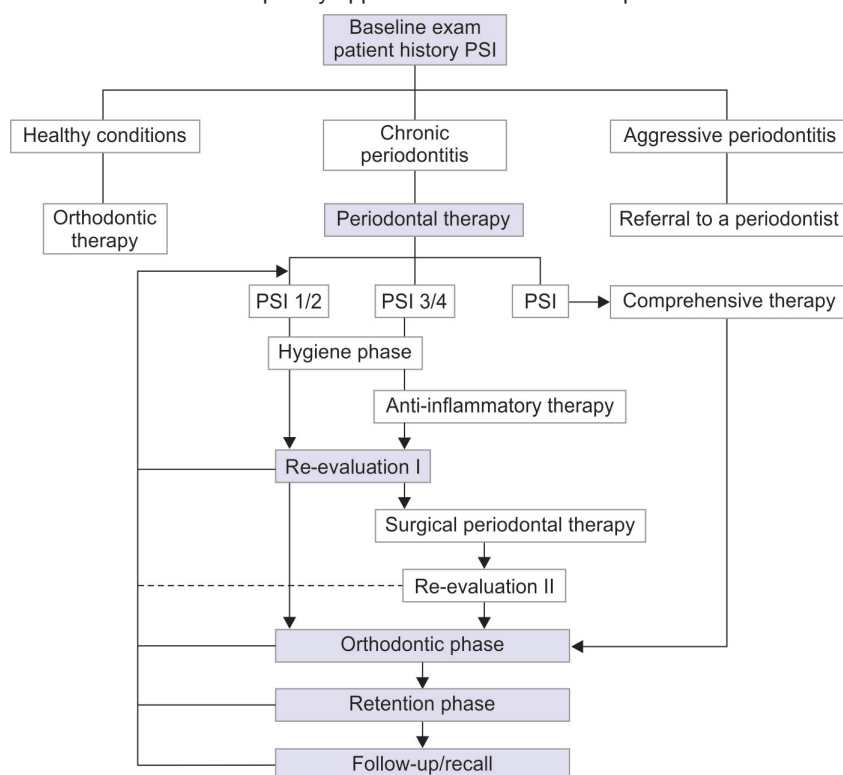
Unfortunately, there is no evidence-based orthodontic therapy for patients with periodontal damage. Nevertheless, we aimed to present ideas on how to coordinate such treatment between disciplines (Flow Chart 1).

BENEFITS OF ORTHODONTICS TREATMENT FOR A PERIODONTAL PATIENT

Orthodontic therapy can provide several benefits to the adult patient with periodontal problems. The following six factors should be considered:

1. Aligning crowded or malposed maxillary or mandibular anterior teeth permit the adult patient better access to adequately clean all surfaces of their teeth.

Flow Chart 1: Interdisciplinary approach in orthodontic and periodontal treatment



This could be a tremendous advantage for patients who are susceptible to alveolar bone loss or those who do not have the dexterity to adequately maintain their oral hygiene.

2. Vertical orthodontic tooth repositioning can improve certain types of osseous defects in periodontal patients. Often, the tooth movement eliminates the need for resective osseous surgery.
3. Orthodontic treatment can improve the esthetic relationship of the maxillary gingival margin levels before restorative dentistry. Aligning the gingival margins orthodontically avoids gingival recontouring, which potentially could require bone removal and exposure of the roots of the teeth.
4. A patient who has suffered a severe fracture of a maxillary anterior tooth requires forced eruption to permit adequate restoration of the root. In this situation, extruding the tooth allows the crown preparation to have sufficient resistance form and retention for the final restoration.
5. Orthodontic treatment allows open gingival embrasures to be corrected to regain lost papilla. If these open gingival embrasures are located in the maxillary anterior region, they can be unesthetic. In most patients, these areas can be corrected with a combination of orthodontic root movement, tooth reshaping, and/or restoring.
6. Orthodontic treatment could improve adjacent tooth position before implant placement or tooth replacement. This is especially true for the patients having missing teeth for several years and drifted adjacent teeth in the edentulous space.¹³

ORTHODONTIC PROCEDURES FOR THE ENHANCEMENT OF PERIODONTAL CONDITION

Various malocclusions like crowding, tipping, buccoversion, and labioversion have the potential to contribute to periodontal diseases, as they restrict the ability to maintain oral hygiene. Though regular professional periodontal care can restrict the progress of periodontal disease, it is vital to correct the cause rather than managing the effect. This requires placing the teeth in alignment over the basal bone in harmony with the periodontal structures so that proper periodontal care is maintained by the patients themselves. The orthodontist plays the major role by positioning teeth so that necessary oral hygiene can be maintained.

ADVERSE EFFECTS OF ORTHODONTIC PROCEDURES ON THE PERIODONTAL TISSUES

Gingival Inflammation, Hyperplasia, and Periodontal Pathogens

Many past studies have mentioned besides decalcification, which leads to white spots and eventually caries,

several types of gingivitis, periodontitis, gingival recession, and the formation of gingival pockets had been noted during and/or after orthodontic treatment.¹⁴ It has been also shown that different species of bacteria, such as *Bacterioids intermedius*, spirochetes, motile rods, *B. forsythus*, *T. dentcola*, *P. nigrescens*, *C. rectus*, and fusiform were considered to increase more frequently in the dental plaque of patients undergo orthodontic treatment.¹⁰²

Occurrence of Gingival Invagination

Gingival invaginations are defined as superficial changes in the shape of gingiva, which arise after moving the teeth orthodontically in order to close the spaces resulted from extraction. Gingival invaginations vary from slight fissures located in the keratinized¹⁰⁵ gingiva to deep gaps crossing the interdental papilla buccally or lingually through the alveolar bone deeply.¹⁵

MINOR PERIODONTAL SURGERY ASSOCIATED WITH ORTHODONTIC THERAPY

Fiberotomy

The problem of relapse of orthodontically treated teeth, in general, and rotated teeth, in particular, has been well recognized for years. Methods to reduce the occurrence of rotational relapse may include: (1) Complete correction, or overcorrection, of rotated teeth, (2) long-term retention with bonded lingual retainers, and (3) the use of fiberotomy.

Frenotomy

The contribution of the maxillary labial frenum to the etiology of a persisting midline diastema and to reopening of diastemas after orthodontic closure is controversial. However, very hyperplastic types of frenum, with a fan-like attachment, may obstruct diastema closure and should be relocated.

Removal of Gingival Invaginations (Clefts)

Incomplete adaptation of supporting structures during orthodontic closure of extraction spaces in adults may result in folding or invagination of the gingiva. The clinical appearance of such invaginations may range from a minor one-surface crease to deep clefts that extend across the interdental papilla from the buccal to the lingual gingivae. Edwards suggested that simple removal of only the excess gingiva in the buccal and lingual area of approximated teeth would be sufficient to alleviate the tendency for the teeth to separate after orthodontic movement.¹⁶

Gingivectomy

If a gingival margin discrepancy is present, but the patient's lip does not move upward to expose the

discrepancy upon smiling, it does not require correction. If the gingival discrepancy is apparent, however, one of four different techniques may be used:

1. Gingivectomy
2. Intrusion + incisal restoration or porcelain laminate veneer
3. Extrusion + fiberotomy + porcelain crown
4. Surgical crown lengthening, by flap procedure and ostectomy/ostoplasty

Surgical Exposure of Unerupted Tooth

Excision of gingival tissue over the embedded tooth used to be a popular approach to achieve crown exposure. However, the result is usually accomplished at the expense of the keratinized tissue covering the unerupted teeth. In order to avoid this problem, an improved technique for the preservation of existing keratinized tissue was developed, which involves the repositioning of existing keratinized tissue.

Alveolar Ridge Augmentation

The dimension of the alveolar ridge is an important consideration prior to orthodontics movement. Therefore, in such instances, the ridge is augmented using bone grafts, hydroxyapatite crystals, etc. These procedures are aimed at correcting the excessive loss of alveolar bone that sometime occur as a consequence of advanced periodontal disease, advanced periapical bone loss, traumatic tooth extraction, external trauma, and so forth.

Mucogingival Surgery

The lack of keratinized gingiva is one of the most common complications following orthodontic movement. Pre-orthodontic mucogingival surgery is indicated for teeth with an inadequate zone of keratinized gingiva, to prevent mucogingival involvement post-orthodontically, which is more difficult to treat.¹⁷

ORTHODONTIC TREATMENT OF GINGIVAL DISCREPANCIES

Uneven Gingival Margins

These discrepancies could be caused by abrasion of the incisal edges or delayed migration of the gingival margins, when gingival margin discrepancies are present, the proper solution for the problem must be determined: Orthodontic tooth movement to reposition the gingival margins or surgical correction of gingival margin discrepancies.

Open Gingival Embrasures

The presence of a papilla between the maxillary central incisors is a key esthetic factor in any individual. This

open space is usually due to one of three causes: Tooth shape, root angulation, or periodontal bone loss. If a patient has an open embrasure, the first aspect that must be evaluated is whether the problem is due to the papilla or the tooth contact. If the papilla is the problem, then the cause is usually a lack of bone support due to an underlying periodontal problem. In some situations, a deficient papilla can be improved with orthodontic treatment. By closing open contacts, the interproximal gingiva can be squeezed and moved incisally. Another possibility is to erupt adjacent teeth when the interproximal bone level is positioned apically.

ORTHODONTIC TREATMENT OF OSSEOUS DEFECTS

Hemiseptal Defects

Hemiseptal defects are one- or two-wall osseous defects that often are found around mesially tipped teeth or teeth that have supraerupted. Usually, these defects can be eliminated with the appropriate orthodontic treatment. In the case of the tipped tooth, uprighting and eruption of the tooth levels the bony defect. If the tooth is supraerupted, intrusion and leveling of the adjacent cementoenamel junctions can help level the osseous defect.

Advanced Horizontal Bone Loss

In a patient with advanced horizontal bone loss, the bone level may have receded several millimeters from the CEJ. As this occurs, the crown-to-root ratio becomes less favorable. This could require periodontal surgery to ameliorate the discrepancies. Many of these problems can be corrected by using the bone level as a guide to position the brackets on the teeth. In these situations, the crowns of the teeth may require considerable equilibration.

Furcation Defects

Furcation defects can be classified as incipient (class I), moderate (class II), or advanced (class III). These lesions require special attention in the patient undergoing orthodontic treatment, because they are the most difficult lesions to maintain and can worsen during orthodontic therapy. These patients need to be maintained on a 2- to 3-month recall schedule. Detailed instrumentation of these furcations helps minimize further periodontal breakdown.^{16,17}

Root Proximity

When roots of posterior teeth are in close proximity, the ability to maintain periodontal health and accessibility for restoration of adjacent teeth may be compromised. However, if the patient were undergoing orthodontic

therapy, the roots can be moved apart and bone will be formed between the adjacent roots.

RECENT TRENDS

Possible Combined Future Researches in the Field of Orthodontics and Periodontics

Saliva biomarkers: Orthodontic tooth movement is a process of paradental remodeling mediated by inflammatory mediators like PGE2s, cytokines, neuropeptides, MMPs, etc. These inflammatory mediators are also present in periodontitis and periodontal diseases. Hence, detection of these inflammatory mediators is of paramount importance in detection and screening of periodontal diseases as well as demonstrating orthodontic tooth movement. GCF markers have several shortcomings like long collection times, easy proneness to contamination, thick viscosity, questionable accuracy, etc. Salivary biomarkers are rapidly gaining increasing popularity over GCF markers these days.

Advantages include: (1) Inexpensive, noninvasive, and easy-to-use; (2) ease of collection, storing, and shipping; and (3) easier handling as it does not clot.

Disadvantages include: (1) Informative analytes generally present in lower amounts than in serum and (2) dilution of biomarkers common.

Periodontally Accelerated Osteogenic Orthodontics/Distractor Osteogenesis of the Periodontal Ligament

Distractor osteogenesis is the process of growing new bone by mechanical stretching of preexisting bone tissue. A new concept of distracting the PDL is proposed to elicit canine retraction in 3 weeks. This is called dental distractor. The PDL acts as a suture between the bone and the tooth.

Wilco et al. and Nazarow et al.¹⁸ demonstrated that adding periodontal regenerative surgery to the orthodontic protocol increased the quality of care in terms of clinical outcome and long-term stability. Surgically accelerated modalities like selective alveolar decortication (SAD) and periodontally accelerated osteogenesis orthodontics can be used as an adjunct to conventional approaches to accelerate OTM with fewer adverse effects. SAD is a procedure where linear and punctuate decortications are made after reflecting the flap. The decortications should not impinge on root-PDL-cribriform plate complex and not extend to the alveolus crest. Accelerated OTM occurs due to inflammation and wound-healing processes that are evoked by surgical trauma to alveolar bone. In addition, alveolar bone surgery may also stimulate production of MSCs in marrow cavities, which function

synergistically with neighboring PDL and alveolar bone cells, resulting in accelerated OTM.

Murphy demonstrated that addition of bone graft to a tooth moving through a surgical wound increases bone mass and enhances long-term stability. Frost investigated this phenomenon in depth and coined it as the "regional acceleratory phenomenon" and found that the normal metabolic rate of inflammation and wound healing process is accelerated.^{19,20}

REFERENCES

1. Ong-Wang et al, AJODO 2002;122:420-428.
2. Klein DC, Raisz LG. Prostaglandins: Stimulation of bone resorption in tissue culture. *Endocrinology* 1970;86: 1436-1440.
3. Sandy JR, Farndale RW, Meikle MC. Recent advances in understanding mechanically induced bone remodeling and their relevance to orthodontic theory and practice. *Am J Orthod Dentofacial Orthop* 1993;103:212-222.
4. Krishnan V, Davidovitch Z. Cellular, molecular, and tissue-level reactions to orthodontic force. *Am J Orthod Dentofacial Orthop* 2006;129:469.e1-32.
5. Raisz LG. Physiology and pathophysiology of bone remodeling. *Clin Chem* 1999;45:1353-1358.
6. Teitelbaum SL, Ross FP. Genetic regulation of osteoclast development and function. *Nat Rev Genet* 2003;4:638-649.
7. Davidovitch Z, Nicolay OF, Ngan PW, Shanfeld JL. Neurotransmitters, cytokines, and the control of alveolar bone remodeling in orthodontics. *Dent Clin North Am* 1988;32: 411-435.
8. Theoleyre S, Wittrant Y, Tat SK, Fortun Y, Redini F, Heymann D. The molecular triad OPG/RANK/RANKL: Involvement in the orchestration of pathophysiological bone remodeling. *Cytokine Growth Factor Rev* 2004;15: 457-475.
9. Kanzaki H, Chiba M, Takahashi I, Haruyama N, Nishimura M, Mitani H. Local OPG gene transfer to periodontal tissue inhibits orthodontic tooth movement. *J Dent Res* 2004;83:920-925.
10. Yamaguchi M, Aihara N, Kojima T, Kasai K. RANKL increase in compressed periodontal ligament cells from root resorption. *J Dent Res* 2006;85:751-756.
11. Lee KJ, Park YC, Yu HS, Choi SH, Yoo YJ. Effects of continuous and interrupted orthodontic force on interleukin-1beta and prostaglandin E2 production in gingival crevicular fluid. *Am J Orthod Dentofacial Orthop* 2004;125:168-177.
12. Meyle J, Jepsen S. Der parodontale Screening-Index (PSI). *Parodontologie* 2000;11:17-21.
13. *Am J Orthod* 1985;87:67-73.
14. Trossello VK, Gianelly AA. Orthodontic treatment and periodontal status. *J Periodontol* 1979 Dec;50(12):665-671.
15. Ronnerman A, Thilander B, Heyden G. Gingival tissue reactions to orthodontic closure of extraction sites. *Histologic and histochemical studies. Am J Orthod* 1980 Jun;77(6): 620-625.
16. Lindhe J clinical periodontics/implant dentistry 5th edipg 1275.
17. Kokich VG. Esthetic. The orthodontic-periodontic restorative connection. *Semin Orthod* 1996;2:21-30.

18. Nazarow AD, Ferguson DJ, Wilckco WM, Wilcko MT. Improved orthodontics retention following corticotomy using ABO oblective grading system. J Dent Res 2004;83 Abs 2644Shapiro E, Roeber FW, Klempner LS. Orthodontic movement using pulsating force-induced piezoelectricity. Am J Orthod 1979;76:59-66.
19. Kole H. Surgical operations on the alveolar ridge to correct occlusal abnormalities. Oral Surg Oral Med Oral Pathol 1959;12:515-529.
20. Hosl E, Baldauf A, editors. Mechanical and Biological Basics in Orthodontic Therapy. Heidelberg: Huthig Buch Verlag; Corticotomy in orthodontics; 1991 pp. 207-226.